

Ultrasound Anatomic Demonstration of the Infrapatellar Nerve Branches



Georg Riegler, M.D., Suren Jengojan, M.D., Johannes A. Mayer, M.D.,
Christopher Pivec, M.D., Hannes Platzgummer, M.D., Peter C. Brugger, M.D., Ph.D.,
Oskar Aszmann, M.D., and Gerd Bodner, M.D.

Purpose: To (1) confirm the correct identification of the infrapatellar branches of the saphenous nerve (IPBSNs) by high-resolution ultrasound (HRUS) with ink marking and consecutive dissection in anatomic specimens; (2) evaluate the origin, course, and end-branch distribution in healthy volunteers; and (3) visualize the variable anatomic course of the IPBSN by HRUS. **Methods:** HRUS with high-frequency probes (15-22 MHz) was used to locate the IPBSN in 14 fresh anatomic specimens at 4 different locations. The correct identification of the IPBSN was verified by ink marking and consecutive dissection. Moreover, the IPBSNs were located in both knees of 20 healthy volunteers (n = 40). Their courses were marked on the volunteers' skin in a flexed-knee position. Distances were measured from the IPBSN branch closest to the median of the patella base (D1), center (D2), and apex (D3) and in a 45° (D4) and 0° (D5) relation to the median patella apex. Standardized photographs of all knees were mapped on 1 typically shaped knee. **Results:** Dissection confirmed the correct identification of the IPBSN in 86% to 100% of branches, depending on their location. Intra-individual differences for distance measurements were observed for D1 ($P < .001$) and D2 ($P = .002$). The coefficient of variation was highest for D5 (0.86) and lowest for D1 (0.14). Mapping of the nerve branches on a typical knee showed a highly variable course for the IPBSN. **Conclusions:** This study confirmed the reliable ability to visualize the IPBSN and its variations with HRUS in anatomic specimens and in healthy volunteers; such visualization may therefore enhance the diagnostic and therapeutic management of patients with anteromedial knee pain. **Clinical Relevance:** Ultrasound successfully pinpoints the variable course of the IPBSN from the origin to the most distal point and, therefore, may enable the correct identification of (iatrogenic) nerve damage in every location.

See commentary on page 2884

The infrapatellar branches of the saphenous nerve (IPBSNs) are pure sensory nerves that supply innervation to the skin over the anteromedial aspect of the knee and to medial knee joint structures.^{1,2} These nerves (Fig 1) show a high variability with regard to their (1) origin from the saphenous or femoral nerve³; (2) course through the adductor canal⁴; (3) relation to the sartorius muscle^{1,3}; and (4) branching and

distribution at the infrapatellar, anteromedial side of the knee.^{5,6}

The main clinical relevance of these branches is their susceptibility to iatrogenic injury, with clinical symptoms occurring in 10% to 100% of patients after total knee arthroplasty,^{7,8} surgical meniscectomy,⁹ arthroscopy and anterior cruciate ligament reconstruction, and tibial nailing.¹⁰⁻¹² Trauma to¹³ or entrapment of the

From the Department of Biomedical Imaging and Image-guided Therapy (G.R., S.J., C.P., H.P., G.B.); Department of Surgery, Division of Plastic and Reconstructive Surgery (J.A.M., O.A.); and Department of Anatomy, Center for Anatomy and Cell Biology (P.C.B.), Medical University of Vienna, Vienna, Austria.

The authors report the following potential conflict of interest or source of funding: Funding for this study was received from the Medical Scientific Fund of the Mayor of the City of Vienna. G.R. receives support from Mayor of the City of Vienna (Project No. 15200). Full ICMJE author disclosure forms are available for this article online, as [supplementary material](#).

Paper previously presented at: European Congress of Radiology, Vienna, Austria, March 1–5, 2017, and the XXVI International Conference on Sports

Rehabilitation and Traumatology—The Future of Football Medicine, Barcelona, Spain, May 13–15, 2017.

Received November 30, 2017; accepted May 28, 2018.

Address correspondence to Georg Riegler, M.D., Department of Biomedical Imaging and Image-guided Therapy, Medical University of Vienna, Währingergürtel 18-20, 1090 Vienna, Austria. E-mail: georg.riegler@meduniwien.ac.at

© 2018 by the Arthroscopy Association of North America
0749-8063/171414/\$36.00

<https://doi.org/10.1016/j.arthro.2018.05.043>

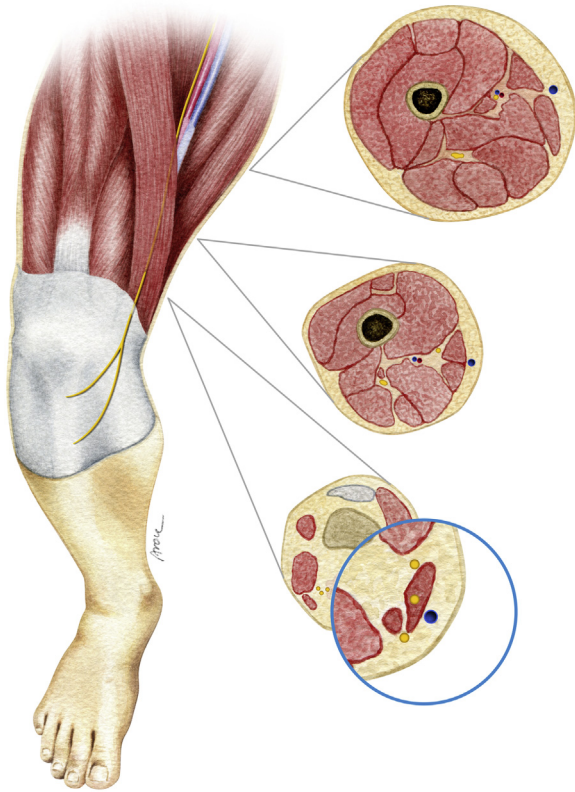


Fig 1. Illustration of course of infrapatellar branch of saphenous nerve in a right knee. The possible relation of the branch to the sartorius muscle is shown in the distal-most transverse image.

IPBSN¹⁴ is reported less often. Clinical symptoms after IPBSN damage may vary from mild symptoms, such as irritating paresthesia or hypesthesia, to severe pain,^{15,16} and a relation between damage to the branch and reflex sympathetic dystrophy has also been described.^{17,18}

Recent studies have shown that patient comfort after tibial nailing⁸ or arthroplasty¹⁹ is inversely correlated with the presence of IPBSN injury. Moreover, denervation for persistent neuroma pain of the IPBSN significantly improved patients' visual analog pain scores.²⁰ Hence, *in vivo* evaluation of the IPBSN, as well as its variability and pathology, is desirable to reduce potential iatrogenic injury to the branch or improve operative planning and, therefore, the management of patients with IPBSN neuropathy. To date, 3 studies are available that have documented the course of the IPBSN.²¹⁻²³ However, these studies did not take into account the high variability and topographic significance of these branches to various surgical interventions around the knee. In addition, there were no detailed measurements or visualizations of nerve variability or imitation of intraoperative settings. Because high-resolution ultrasound (HRUS), using probes of high frequency, offers excellent tissue differentiation for the examination of superficial structures, an

accurate depiction of the IPBSN over the entire course seems possible.

This study aimed to (1) confirm the correct identification of the IPBSN by HRUS with ink marking and consecutive dissection in anatomic specimens; (2) evaluate the origin, course, and end-branch distribution in healthy volunteers; and (3) visualize the variable anatomic course of the IPBSN by HRUS. We hypothesized that, using this technique, an evaluation of the variable course of the IPBSN would be possible over the entire track.

Methods

Study Approval

This was a single-center, prospective study. The study was approved by the local institutional review board of the Medical University of Vienna (project No. 1377/2016) and was conducted between July 2016 and July 2017. The study was performed in accordance with the World Medical Association Declaration of Helsinki.

Ultrasound in Anatomic Specimens

In 14 limbs of 7 randomly selected fresh anatomic specimens, in the legal custody of the Department of Systematic Anatomy, Medical University of Vienna, HRUS was performed as described. After the IPBSN was located, a small amount of blue dye mixed with glue (0.1 mL) was injected into the nerve or adjacent to the nerve under HRUS guidance (22-gauge needle, in-plane technique) at 4 different locations: at its origin from the saphenous nerve (R1), at the fat pad superficial to the sartorius muscle (R2), at the tibiofemoral joint line (R3), and in the infrapatellar region (at least 1 branch) (R4). Subsequent anatomic dissection was performed to confirm the exact location of the dye injection. The plastic surgeon (J.A.M.) and anatomist (P.C.B.) who performed the dissections determined the exact location of the ink application. Correct dye injection was noted if at least some amount of the dye was injected into the nerve sheath at all 4 distinct locations. In all specimens, distribution of the injected ink was documented by photography.

Ultrasound in Healthy Volunteers

Volunteers. Twenty healthy volunteers were recruited through notices at the Department of Biomedical Imaging and Image-guided Therapy and word-of-mouth acquisition. Written informed consent was obtained from all volunteers. The inclusion criterion was age older than 18 years, and the exclusion criteria were any known polyneuropathy, myopathy, chronic disease that caused peripheral neuropathy, current or previous knee pain, and previous knee surgery. The age, size, weight, and body mass index (BMI) of all

volunteers were assessed or calculated before the examination using a scale and measuring tape.

Ultrasound. The IPBSN and its branches were assessed on both sides ($n = 40$). The examination began with healthy volunteers lying in a supine position with the knees extended as described earlier. First, the IPBSN and its branches were assessed over the entire course. After identification, the visibility of the IPBSN was rated using a 5-point scale as follows: excellent (i.e., sharply defined border and visible internal nerve structure with excellent diagnostic quality) (5); good (i.e., good diagnostic quality, clearly distinguishable from surrounding tissue, with internal nerve structure visible) (4); moderate (i.e., identifiable but no sharp border with surrounding tissue and no internal nerve structure visible) (3); poor (i.e., identified with difficulty and identification only possible if adjacent IPBSN sections were followed) (2); or not visible (1). Before scoring, 5 figures of peripheral cutaneous nerves were obtained by the raters, which showed examples of ratings from “excellent” to “not visible.” These examples were used to match the findings and obtain the visibility score. The visibility of the IPBSN was rated at the same 4 distinct anatomic regions used for dye injection. Moreover, the relation of the IPBSN to the sartorius muscle during its course was assessed. Either the IPBSN was located anterior or posterior to the sartorius muscle or it pierced the muscle (penetrating type). The number of branches was determined.

Measurements. For further evaluations, all knees were flexed into a 90° angle (confirmed with a goniometer), simulating the intraoperative position for most anteromedial knee surgical procedures. Then, the courses of the nerve and its branches were marked with a washable surgical skin marking pen on the volunteers’ skin. For this reason, the branch was positioned exactly in the middle of the ultrasound image, as indicated by a small, yellow arrowhead at the upper border of the ultrasound image. The branch was then marked perpendicular to the outer marking of the ultrasound probe, which indicated the center of the probe. The branch was marked every 2 to 3 cm, and the lines were connected.

Osseous and non-osseous landmarks were placed as a reference for measurements and calculations. Different distance measurements from the reference points of the patella were obtained. When the nerve split into 2 or more branches, the branch closest to the reference point was used to calculate intraindividual differences (differences between right and left sides) and differences between sexes. The measurements were performed using a measuring tape. The distance between the marked line on the skin and the reference points was measured along the circumference of the limb.

Ultrasound Technique

Examinations were performed using a GE LOGIQ E9 and GE LOGIQ e ultrasound platform (GE Healthcare, Wauwatosa, WI) with high-frequency probes (GE ML 6-15-D, GE L8-18i-D, and GE L10-22-RS). Two radiologists carried out all examinations: One had more than 20 years’ experience (G.B.) whereas the other had 4 years’ experience (G.R.) in peripheral nerve imaging. Both radiologists were present during the recruitment of the individuals. G.B. performed all interventions on all anatomic specimens while G.R. watched the procedures. G.R. collected all images and performed measurements on healthy individuals while G.B. watched the procedures.

The examination followed a standardized assessment protocol. All participants were examined in the supine position, with the knees extended. The ultrasound examination started with the transverse view of the sartorius muscle and vastus medialis muscle approximately 10 to 15 cm above the knee joint line. The sartorius muscle was then carefully screened distally until a tubular structure that pierced the fascia lata overlying the sartorius muscle was reached, and the nerve lying in a fat pad was assumed to be the IPBSN. The morphology and course of the IPBSN and its relation to the surrounding structures were then analyzed in real time during imaging. To correctly assign the IPBSN to the origin from the saphenous nerve, the former was followed proximally until its origin. Then, the IPBSN was traced distally, crossing the medial tibiofemoral joint line until the branch subdivided into the terminal branches. If detectable, all branches were followed until their most distally visible part was reached.

To obtain a better overview of the area, the examination always started with the GE ML 6-15-D probe. After the IPBSN was identified and its origin assessed, the transducer was changed in most cases, and a GE L8-18i-D or GE L10-22-RS probe was used to improve the delineation of the branch at its superficial course around the anteromedial knee side. At its origin, a careful evaluation of depth (approximately 3-12 cm, depending on the thigh thickness of humans) and angulation of the transducer to avoid anisotropy (the nerve runs obliquely from a superficial to a deep course to reach the origin) must be performed to ensure that the nerve is in full view and not distorted on the image.

Ultrasound-Guided Anatomy Mapping

To visualize and evaluate the variable anatomy of the IPBSN, we relied on the anatomy mapping tool “computer assisted surgical anatomy mapping,” previously described by Kerver et al.⁵ First, we photographed the anterior and medial sides of all knees with an iPhone SE camera (Apple, Cupertino, CA) using a standardized assessment protocol. All healthy volunteers were positioned in 90° of knee flexion (confirmed

with a goniometer) at the height-adjustable edge of the bed. For anterior knee views, the camera was positioned 35 cm in front of the knee at a height of 35 cm with a 90° angle from the floor. The apex–tuberosity line was used as the midline for photographs. The bed and camera positions were maintained during each of the measurements on the volunteers, as indicated by marked crosses on the floor, but with only slight adaptations of the camera position if the volunteer's knee was not exactly 35 cm in front of the camera. For medial knee views, the same camera-position distances were used, and these were also marked with crosses on the floor. The anterior margin of the medial femoral plateau, crossing the medial tibial plateau, was used as the midline for photographs. Special attention was paid to maintain a neutral position between internal and external knee rotation in all volunteers.

Second, we used Adobe Photoshop CS6 image-processing software (Adobe Systems, San Jose, CA) to define the shape and size of each leg using 3 osseous landmarks: (1) the patella apex, (2) the anterior margin of the medial femoral plateau crossing the medial tibial plateau, and (3) the center between the medial tibial plateau and the medial malleolus. This was followed by a calculation of the average shape and size of all legs. Thereafter, all legs in all pictures were reshaped to exactly match the shape and size of the created and calculated average leg. As a result, all the legs in all the pictures had the exact same shape and size, and the anatomy of the IPBSN in all specimens could be mapped and visualized in 1 average-shaped knee.

Statistical Analysis

Using IBM SPSS Statistics for Windows (version 22.0.0.2; IBM, Armonk, NY), our statistician performed all statistical computations. Metric data, such as distance, age, size, weight, and BMI, are presented as mean (\pm standard deviation) and range (minimum to maximum). For the nerve visibility score, the median, minimum, and maximum were used. To compare differences between distance measurements of the left and right IPBSN in healthy volunteers, a paired Student *t* test was performed. To evaluate differences between distance measurements of the IPBSN in women and men, an unpaired Student *t* test was performed. Pearson correlation coefficients were used to assess distance measurement correlations between the left-right and female-male IPBSN positions in healthy volunteers. The variability of distance measurements was assessed using the coefficient of variation. This coefficient was calculated as the ratio between the standard deviation and the mean of distance measurements. In cases in which the differences were nearly significant, a sample size calculation was added. A *P* value equal to or below 5% was considered statistically significant.

Results

Ultrasound Accurately Pinpoints IPBSN in Anatomic Specimens

We used anatomic specimens to determine whether the application of ultrasound to the anteromedial knee would assist in predicting the exact location of the IPBSN. During sonography, small amounts of dye were injected at sites that correlated with nerve positions R1, R2, R3, and R4, namely, the origin, the fat pad superficial to the sartorius muscle, the tibiofemoral joint line, and the infrapatellar region, respectively. Dissection confirmed the correct identification of the IPBSN in 14 of 14 branches (100%) at R1, R3, and R4 and 12 (86%) of 14 branches at R2. In 2 of the first 3 ink-infiltrated and dissected cases (Figs 2 and 3), we confounded the IPBSN with the medial branch of the femoral cutaneous nerve (MFCN)²⁴ at the fat pad that is superficial to the sartorius muscle (R2). We further analyzed the ultrasound images, as well as the investigation protocols, and assumed that the MFCN always ran anterior to the IPBSN, approximately 10 cm above the knee, and did

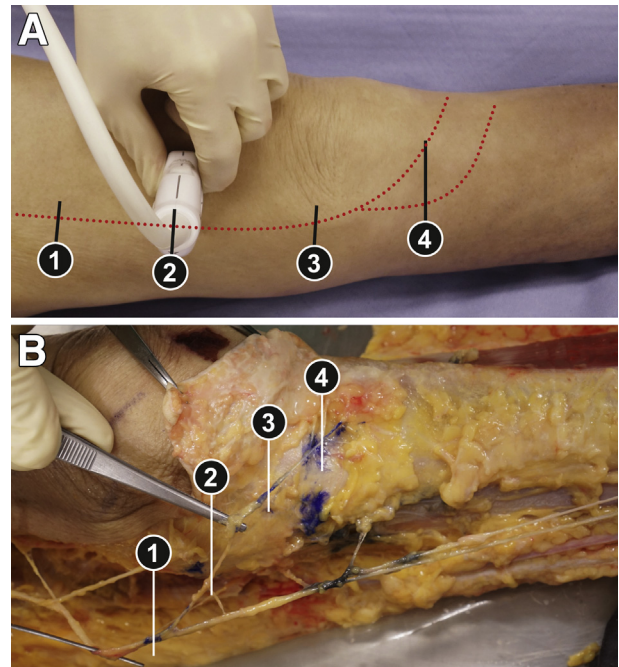


Fig 2. (A) Ultrasound probe positioning for evaluation of the infrapatellar branch of the saphenous nerve (IPBSN) at 4 different anatomic locations in a left knee: (1) at the origin from the saphenous nerve, (2) at the fat pad superficial to the sartorius muscle, (3) at the tibiofemoral joint line, and (4) in the infrapatellar region. The red dotted line indicates the track of the probe for the full IPBSN examination. To obtain transverse views of the IPBSN, the probe orientation must be perpendicular to the dotted line. (B) Example of a finding in a dissection after high-resolution ultrasound-guided intra-nerve ink marking of the IPBSN (blue dye) in a left knee. The saphenous nerve is marked with black dye.

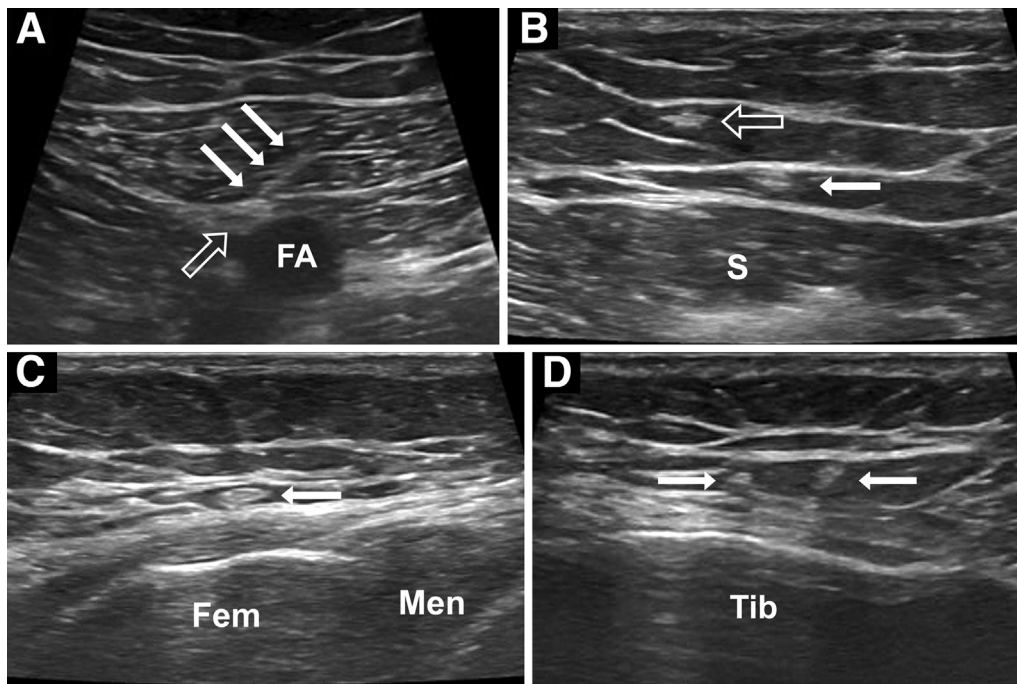


Fig 3. Transverse sonographic images of the infrapatellar branch of the saphenous nerve obtained (1) at the origin from the saphenous nerve (A), (2) at the fat pad superficial to the sartorius muscle (B), (3) at the medial tibiofemoral joint line (C), and (4) in the infrapatellar region (D). The images were obtained from a volunteer's left side (A) or from a volunteer's right side (B-D). The numbers 1 through 4 correspond to the anatomic locations shown in Figure 2. The filled arrows indicate the infrapatellar branch of the saphenous nerve, and the open arrows indicate the saphenous nerve (1) or medial femoral cutaneous nerve (2). (FA, femoral artery; Fem, femur; Men, meniscus; S, sartorius muscle.)

not reach the infrapatellar area. Instead, we found that the MFCN ended at—or above—the level of the medial border of the patella (Fig 3). Nevertheless, this branch almost always crossed the IPBSN during its course upward to its origin. In such cases, the MFCN lay in a fat pad above the IPBSN, whereas the latter ran in a fat pad beneath layer I, almost always penetrating it, when the MFCN already coursed anteriorly. In all further cases, we could correctly identify the IPBSN, as confirmed by correct ink marking. Hence, HRUS appeared to be a useful tool for localizing the IPBSN in anatomic samples, and it would be interesting to apply ultrasound to track the course of the IPBSN as it meanders in the anteromedial knee region of humans.

Ultrasound Shows Highly Variable Course of IPBSN in Healthy Volunteers

To show the variability of the position of the IPBSN in humans, HRUS was applied to 40 knees. Ten women (mean age, 28.5 years; age range, 22-43 years; average BMI, 21.4) and ten men (mean age, 24.7 years; age range, 21-30 years; average BMI, 23.2) were included in the study (overall mean age, 26.2 years; age range, 21-43 years; average BMI, 22.3).

The results showed that the IPBSN could be visualized in both limbs of all 40 volunteers. The median

score for visibility was 4 (minimum, 2; maximum, 5) at its origin from the saphenous nerve (R1), 5 (minimum, 4; maximum, 5) for the fat pad superficial to the sartorius muscle (R2), 3 (minimum, 1; maximum, 5) at the tibiofemoral joint line (R3), and 4 (minimum, 2; maximum, 5) in the infrapatellar region (R4). The relation of the IPBSN to the sartorius muscle was 50% penetrating, 27.5% anterior, and 22.5% posterior. A median of 2 branches was found. The normal sonographic appearance of the IPBSN is shown in Figure 3. Video 1 (available at www.arthroscopyjournal.org) provides an example of the IPBSN in the infrapatellar region in a healthy volunteer's right knee.

In addition, distance measurements in relation to different anatomic landmarks (Fig 4) are provided in Table 1. The coefficient of variation was lowest for D1 (0.14) and highest for D5.1 (0.86). Intraindividual differences and between-sex differences in distance measurements are shown in Tables 2 and 3, respectively. There were significant intraindividual differences between the left and right knees at location D1 ($P < .001$) and location D2 ($P = .002$). No significant differences for distance measurements could be observed between men and women. In the case of nearly statistically significant results ($P = .056$ for D1 and $P = .053$ for D5,

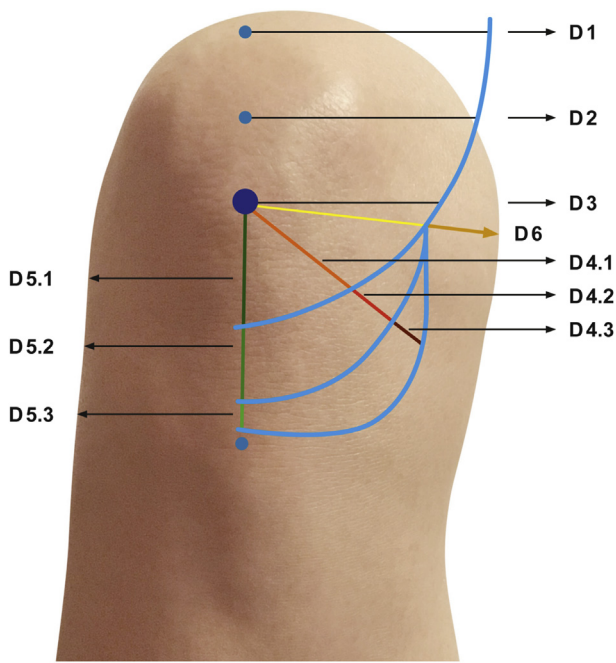


Fig 4. Reference lines for distance measurements are shown on a right knee. From the median base (D1) and the center (D2) of the patella, 1 reference line at 90° was projected over the knees. From the median apex of the patella, 3 reference lines at different angles (90° [D3]; 45° [D4.1, D4.2, and D4.3]; and 0° [D5.1, D5.2, and D5.3]) were projected over the knees for distance measurements from the main trunk (if not yet divided) or the infrapatellar branches of the saphenous nerve (IPBSNs). A sixth line was projected from the median apex of the patella to the division of the main trunk of the IPBSN (D6). The horizontal apex–tuberosity line was drawn from the median apex of the patella to the tibial tuberosity to evaluate the midline crossing of IPBSN branches.

Table 3), a sample size calculation showed that 16 to 20 subjects per group for D1 and 14 to 18 subjects per group for D5 would be needed to obtain a power of 80%. The locations of all the branches of the IPBSN at the anterior knee and medial knee are shown in Figures 5 and 6, respectively. Hence, ultrasound was accurate at pinpointing the course and high variability of the IPBSN in human knees.

Discussion

Ultrasound pinpointed the IPBSN from its origin to its most distal point in anatomic specimens with an accuracy rate of 86% to 100% depending on the location. In healthy volunteers, the IPBSN could be visualized in both limbs, with a median visibility score of 4 (minimum, 2; maximum, 5). In these subjects, the IPBSN showed a highly variable course, with significant intraindividual differences between the left and right knees at the level of the base (D1, *P* < .001) and at the center (D2, *P* = .002) of the patella.

The IPBSN may be injured during knee surgery, sometimes leading to neuropathic sensations and pain. In addition, the course of the IPBSN differs among individuals, enhancing the risk of injury.

According to previously published studies, our results confirm the high variability of the IPBSN at the anteromedial knee.^{5,6,11} Similar to the study by Kerver et al.,⁵ our study also found fewer branches just medial to the patellar tendon at the level of the tibial plateau. Further medially, there were more branches, which makes them prone to iatrogenic injury when anteromedial arthroscopic portals²⁵ are inserted at this level. With regard to possible posteromedial arthroscopic knee portal approaches,²⁶ a safe zone was not definable, which is shown in Figure 6.

Postoperative knee pain can be of neural origin and must be differentiated from other types of pain from a musculoskeletal origin (e.g., implant loosening, infection, or arthritis). If an injury of the IPBSN is suspected, various tools are available to define and localize the site of trauma (e.g., clinical examination, site of scar, type of pain, loss of sensibility, positive Tinel sign, or electrodiagnostic studies).^{15,27} Nevertheless, palpation and percussion are limited by the fact that variations in this area may mimic pathologies related to other nerves (e.g., MFCN²⁴) or other anatomic structures (e.g., medial collateral ligament injury). Electrodiagnostic studies are technically challenging and not useful in the clinical routine. Especially with regard to the level and site of injury, these tests cannot characterize the underlying nerve pathology (e.g., neuroma formation or

Table 1. Distance Measurements of IPBSN in Relation to Different Anatomic Landmarks

	Region	n	Mean, cm	Minimum, cm	Maximum, cm	SD, cm	CV
D1	Patella base	40	12.7	9.0	16.3	1.80	0.14
D2	Patella center	40	10.7	7.0	14.0	1.74	0.16
D3	Patella apex	40	8.4	4.0	13.5	2.01	0.24
D4.1	1. Patella apex 45°	40	3.0	-0.5	7.3	2.19	0.74
D4.2	2. Patella apex 45°	33	5.4	2.3	10.0	1.85	0.34
D4.3	3. Patella apex 45°	4	6.0	4.0	7.3	1.45	0.24
D5.1	1. Patella apex 0°	40	2.3	-0.5	6.5	1.99	0.86
D5.2	2. Patella apex 0°	37	4.7	2.0	11.0	2.44	0.52
D5.3	3. Patella apex 0°	6	6.0	3.5	7.8	1.58	0.26
D6	IPBSN division	36	7.4	0	13.0	2.50	0.34

CV, coefficient of variation; IPBSN, infrapatellar branch of saphenous nerve; SD, standard deviation.

Table 2. Intraindividual Differences in Distance Measurements Between Right and Left Knees in Healthy Volunteers

	Region	Side	Mean, cm	SD, cm	P Value for Difference	Correlation Coefficient	P Value for Correlation
D1	Patella base	L	11.8	1.82	<.001*	.523	.018*
		R	13.5	1.36			
D2	Patella center	L	9.9	1.82	.002*	.227	.335
		R	11.5	1.24			
D3	Patella apex	L	8.0	2.40	.191	.298	.215
		R	8.8	1.58			
D4	Patella apex 45°	L	2.5	1.90	.076	.556	.009*
		R	3.4	2.40			
D5	Patella apex 0°	L	1.9	1.72	.066	.622	.003*
		R	2.7	2.21			
D6	IPBSN division	L	7.4	3.20	.751	.382	.130
		R	7.7	1.77			

IPBSN, infrapatellar branch of saphenous nerve; L, left knee; R, right knee; SD, standard deviation.

*Statistically significant.

nerve traction injury). Imaging methods such as magnetic resonance imaging, computed tomography, or scintigraphy are excellent tools for differential diagnosis but are limited by a lower spatial resolution compared with ultrasound and, therefore, cannot show the IPBSN over its entire course.

In this study, we have investigated the course, variability, and relation of the IPBSN to relevant anatomic landmarks using ultrasound, with the intention of proper diagnosis and treatment if damage to the branches occurs. This information is important not only to allow proper morphologic evaluation of the branches but also to help perform an ultrasound-guided infiltration, which sometimes is needed to arrive at the proper diagnosis and to improve the management of patients with anteromedial knee pain. Lundblad et al.²¹ showed the feasibility of IPBSN blockade at the level of its origin from the saphenous nerve. Nevertheless, they reported a concomitant blockade of the saphenous nerve in greater than 50% of patients. A possible explanation for this concomitant blockade may be the relatively high amount of levobupivacaine used (5 mL) and the anatomic

proximity of both nerves at the location used for blockade. Therefore, diffusion of the local anesthetic may lead to this effect. Our work may offer the anatomic background for the exact, selective IPBSN location. Selective blockade could be performed further distally, or even singular branches could be infiltrated. Using a lower amount of local anesthetics, which is sufficient for blocks of such small nerve branches, may further enhance the diagnostic outcome.

Ultrasound was shown to be accurate at pinpointing the IPBSN when applied to anatomic specimens. Moreover, using ultrasound, we were able to map the meandering course of these nerves in human knees *in vivo*.

If neuralgia triggered by IPBSN lesions persists, surgical excision of the branch has been previously described with good success.^{28,29} This information can also help to guide the surgeon in the placement of the initial incision. Because a good outcome was described for ultrasound-guided percutaneous injection of methylene blue to guide surgery *in vivo*³⁰ and *ex vivo*³¹ for different peripheral nerves, this represents another

Table 3. Differences in Distance Measurements Between Male and Female Healthy Volunteers

Region	Sex	Left Knee			Right Knee			
		Mean, cm	SD, cm	P Value for Difference	Sex	Mean, cm	SD, cm	P Value for Difference
D1	M	12.6	2.07	.056	M	14.0	1.45	.137
	F	11.1	1.17		F	13.1	1.15	
D2	M	10.3	2.20	.418	M	11.7	1.31	.473
	F	9.6	1.37		F	11.3	1.18	
D3	M	7.9	2.69	.854	M	9.3	1.63	.143
	F	8.1	2.07		F	8.2	1.37	
D4	M	1.9	1.21	.155	M	3.9	2.36	.397
	F	3.1	2.32		F	2.9	2.48	
D5	M	1.2	0.83	.053	M	2.8	1.94	.853
	F	2.7	2.08		F	2.6	2.55	
D6	M	6.9	3.60	.517	M	7.7	1.76	.602
	F	7.9	2.50		F	7.3	1.90	

F, female; IPBSN, infrapatellar branch of saphenous nerve; M, male; SD, standard deviation.

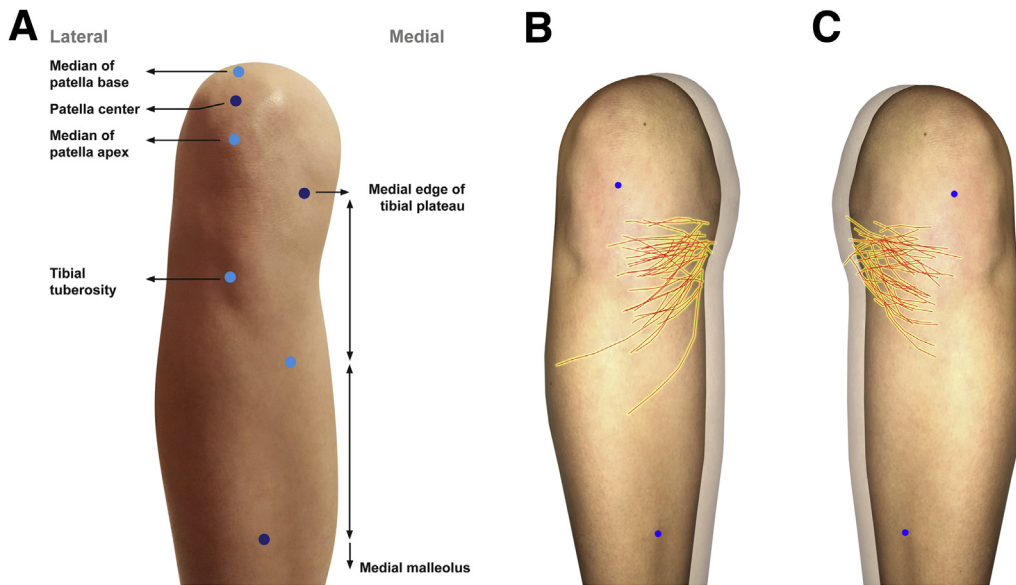


Fig 5. (A) Anterior osseous and non-osseous anatomic landmarks on a right knee. The osseous landmarks were the median of the patella apex, the patella center, the median of the patella base, the tibial tuberosity, the medial and lateral edge of the tibial plateau, and the medial and lateral malleoli (most distal palpable points). (B, C) Non-osseous landmarks were placed at one-fourth the distance between the tibial plateau and the medial malleolus. The location of the infrapatellar branch of the saphenous nerve with ultrasound-guided anatomy mapping generated photographs showing the anatomy of the infrapatellar branch of the saphenous nerve for a knee with average dimensions in the right (B) and left (C) anterior knees. The cranial blue point indicates the average patella apex, and the medial caudal blue point indicates the average middle of the medial tibia.

promising use for this tool. Nevertheless, this topic needs to be addressed by further controlled clinical trials to evaluate its efficacy compared with surgical non-ultrasound-guided procedures.

Our study population of healthy volunteers was young, with a low overall BMI of 22.3. Observations of ultrasound examinations in our daily clinical routine—where, in most cases, patients with knee pain

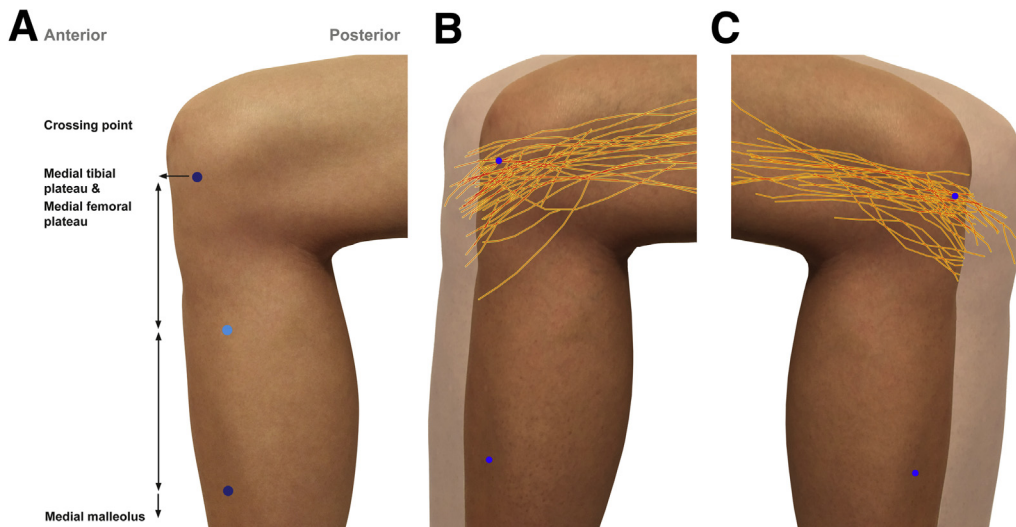


Fig 6. (A) Medial osseous and non-osseous landmarks on a right knee. The osseous landmarks were the crossing point of the medial tibial plateau with the medial femoral plateau and the medial malleolus. (B, C) Non-osseous landmarks were placed at one-fourth the distance between the tibial plateau and the medial malleolus. The location of the infrapatellar branch of the saphenous nerve with ultrasound-guided anatomy mapping generated photographs showing the anatomy of the infrapatellar branch of the saphenous nerve for a knee with average dimensions in the right (B) and left (C) medial knees. Landmarks are indicated with blue points.

present with higher BMIs—show that it is generally easier to track the IPBSN in such patients. This is mainly attributable to the fact that nerves run in fat-filled tunnels³² and, therefore, the contrast to the surrounding tissue is enhanced. Considering this fact, we think that, even in patients with high BMIs, IPBSN evaluation should be possible.

Limitations

Our study has several limitations. We could not match our results with the gold standard of in vivo anatomic dissection, and we cannot exclude the fact that, in some cases, we confounded the IPBSN with the MFCN or other branches of the saphenous nerve. Nevertheless, the ex vivo part of this study was also used to anatomically train the investigators and avoid such a mistake. Another limitation is that marking of the IPBSN on a volunteer's skin may cause some bias (e.g., a branch not exactly in the middle of the ultrasound image because of sliding of the probe during skin marking) and, thus, the anatomic course of the IPBSN may not be shown accurately. Nevertheless, we think that the presented assessment represents "true" anatomic details better than an anatomic study on cadavers in which loose and connective tissue is removed and, therefore, may slightly change the original topographic relations. Further ultrasound-guided mapping of the IPBSN on 1 average-shaped knee cannot fully reflect "true anatomic conditions." Another limitation is that only 1 rater performed the nerve measurements; therefore a definitive statement may not be derived about the diagnostic reliability of IPBSN measurements.

Conclusions

This study confirmed the reliable ability to visualize the IPBSN and its variations with HRUS in anatomic specimens and in healthy volunteers; such visualization may therefore enhance the diagnostic and therapeutic management of patients with anteromedial knee pain.

Acknowledgment

The authors thank Aner Gurvitz and Mary McAllister for their comments on the manuscript, Aron Cserveny for his help on the graphical illustrations, and Michael Weber for his help in the statistical analysis.

References

- Kalthur SG, Sumalatha S, Nair N, Pandey AK, Sequeria S, Shobha L. Anatomic study of infrapatellar branch of saphenous nerve in male cadavers. *Ir J Med Sci* 2015;184: 201-206.
- Horner G, Dellon AL. Innervation of the human knee joint and implications for surgery. *Clin Orthop Relat Res* 1994;221-226.
- Sirang H. Saphenous nerve: Origin, course and branches. *Anat Anz* 1972;130:158-169 [in German].
- Anagnostopoulou S, Anagnostis G, Saranteas T, Mavrogenis AF, Paraskeuopoulos T. Saphenous and infrapatellar nerves at the adductor canal: Anatomy and implications in regional anesthesia. *Orthopedics* 2016;39: e259-e262.
- Kerver AL, Leliveld MS, den Hartog D, Verhofstad MH, Kleinrensink GJ. The surgical anatomy of the infrapatellar branch of the saphenous nerve in relation to incisions for anteromedial knee surgery. *J Bone Joint Surg Am* 2013;95: 2119-2125.
- Kartus J, Ejerhed L, Eriksson BI, Karlsson J. The localization of the infrapatellar nerves in the anterior knee region with special emphasis on central third patellar tendon harvest: A dissection study on cadaver and amputated specimens. *Arthroscopy* 1999;15:577-586.
- Sundaram RO, Ramakrishnan M, Harvey RA, Parkinson RW. Comparison of scars and resulting hypoesthesia between the medial parapatellar and midline skin incisions in total knee arthroplasty. *Knee* 2007;14: 375-378.
- Laffosse JM, Potapov A, Malo M, Lavigne M, Vendittoli PA. Hypesthesia after anterolateral versus midline skin incision in TKA: A randomized study. *Clin Orthop Relat Res* 2011;469:3154-3163.
- Johnson RJ, Kettelkamp DB, Clark W, Leaverton P. Factors effecting late results after meniscectomy. *J Bone Joint Surg Am* 1974;56:719-729.
- Lund B, Nielsen T, Fauno P, Christiansen SE, Lind M. Is quadriceps tendon a better graft choice than patellar tendon? A prospective randomized study. *Arthroscopy* 2014;30:593-598.
- Tifford CD, Spero L, Luke T, Plancher KD. The relationship of the infrapatellar branches of the saphenous nerve to arthroscopy portals and incisions for anterior cruciate ligament surgery. An anatomic study. *Am J Sports Med* 2000;28:562-567.
- Toivanen JA, Vaisto O, Kannus P, Latvala K, Honkonen SE, Jarvinen MJ. Anterior knee pain after intramedullary nailing of fractures of the tibial shaft. A prospective, randomized study comparing two different nail-insertion techniques. *J Bone Joint Surg Am* 2002;84: 580-585.
- Tennent TD, Birch NC, Holmes MJ, Birch R, Goddard NJ. Knee pain and the infrapatellar branch of the saphenous nerve. *J R Soc Med* 1998;91:573-575.
- House JH, Ahmed K. Entrapment neuropathy of the infrapatellar branch of the saphenous nerve. *Am J Sports Med* 1977;5:217-224.
- Trescot AM, Brown MN, Karl HW. Infrapatellar saphenous neuralgia—Diagnosis and treatment. *Pain Physician* 2013;16:E315-E324.
- Kim SJ, Yoon JY, Kim SM, Ha S, Kim SH, Cho I. A comparative study on the postoperative outcomes of anterior cruciate ligament reconstruction using patellar bone-tendon autografts and bone-patellar tendon-bone autografts. *Arthroscopy* 2016;32:1072-1079.
- Poehling GG, Pollock FE Jr, Koman LA. Reflex sympathetic dystrophy of the knee after sensory nerve injury. *Arthroscopy* 1988;4:31-35.

18. Cooper DE, DeLee JC. Reflex sympathetic dystrophy of the knee. *J Am Acad Orthop Surg* 1994;2:79-86.
19. Leliveld MS, Verhofstad MH. Injury to the infrapatellar branch of the saphenous nerve, a possible cause for anterior knee pain after tibial nailing? *Injury* 2012;43:779-783.
20. Dellon AL, Mont MA, Mullick T, Hungerford DS. Partial denervation for persistent neuroma pain around the knee. *Clin Orthop Relat Res* 1996;216-222.
21. Lundblad M, Kapral S, Marhofer P, Lonnqvist PA. Ultrasound-guided infrapatellar nerve block in human volunteers: Description of a novel technique. *Br J Anaesth* 2006;97:710-714.
22. Le Corroller T, Lagier A, Pirro N, Champsaur P. Anatomical study of the infrapatellar branch of the saphenous nerve using ultrasonography. *Muscle Nerve* 2011;44:50-54.
23. Orduna Valls JM, Vallejo R, Lopez Pais P, et al. Anatomic and ultrasonographic evaluation of the knee sensory innervation: A cadaveric study to determine anatomic targets in the treatment of chronic knee pain. *Reg Anesth Pain Med* 2017;42:90-98.
24. Pivec C, Bodner G, Mayer JA, et al. Novel demonstration of the anterior femoral cutaneous nerves using ultrasound [published online February 7, 2018]. *Ultraschall Med*. doi: 10.1055/s-0043-121628.
25. Ward BD, Lubowitz JH. Basic knee arthroscopy part 2: Surface anatomy and portal placement. *Arthrosc Tech* 2013;2:e501-e502.
26. McGinnis MD, Gonzalez R, Nyland J, Caborn DN. The posteromedial knee arthroscopy portal: A cadaveric study defining a safety zone for portal placement. *Arthroscopy* 2011;27:1090-1095.
27. Bademkiran F, Obay B, Aydogdu I, Ertekin C. Sensory conduction study of the infrapatellar branch of the saphenous nerve. *Muscle Nerve* 2007;35:224-227.
28. Nahabedian MY, Johnson CA. Operative management of neuromatous knee pain: Patient selection and outcome. *Ann Plast Surg* 2001;46:15-22.
29. Mistry D, O'Meeghan C. Fate of the infrapatellar branch of the saphenous nerve post total knee arthroplasty. *ANZ J Surg* 2005;75:822-824.
30. Osorio JA, Breshears JD, Arnaout O, et al. Ultrasound-guided percutaneous injection of methylene blue to identify nerve pathology and guide surgery. *Neurosurg Focus* 2015;39:E2.
31. Gofeld M, Bristow SJ, Chiu S, Kliot M. Preoperative ultrasound-guided mapping of peripheral nerves. *J Neurosurg* 2013;119:709-713.
32. Thiel W. *Photographic atlas of practical anatomy*. Berlin: Springer, 1999.