

# Ultrasound study of the asymptomatic shoulder in patients with a confirmed rotator cuff tear in the opposite shoulder

Z Oschman (MB ChB, DCH, MSc (Sports Medicine))<sup>1</sup>

C Janse van Rensburg (MB ChB, MMed (Phys Med), MSc (Sports Medicine))<sup>1</sup>

N G J Maritz (MMed, FCS (Orth) SA)<sup>2</sup>

H Borraine (PhD)<sup>3</sup>

R Owen (BSc (Hons))<sup>3</sup>

<sup>1</sup>Division of Sports Medicine, Department of Orthopaedics, University of Pretoria

<sup>2</sup>Department of Orthopaedics, University of Pretoria

<sup>3</sup>Department of Statistics, University of Pretoria

## Abstract

**Objective.** To document the incidence of asymptomatic rotator cuff tears in patients with a confirmed symptomatic tear in the opposite shoulder, and to identify ultrasound findings that may distinguish symptomatic from asymptomatic tears.

**Design.** When patients are referred for an ultrasound examination for the confirmation of symptomatic rotator cuff tear the opposite shoulder is often used for comparison. However, patients often have a similar tear on the asymptomatic side. Fifty patients with a confirmed symptomatic rotator cuff tear and an asymptomatic shoulder on the opposite side were chosen for inclusion. The patients were examined using a Siemens Sonoline Elegra 7.5 MHz linear multi-frequency probe. The appearance of the rotator cuff, long head of the biceps and the subacromial-subdeltoid bursa (SASD bursa) were documented. The antero-posterior (AP) dimension of the supraspinatus muscle and fat between the trapezius and supraspinatus muscles were measured, which indicated if a tear was acute or chronic. The width and length of the rotator cuff tear were measured.

**Setting.** Division of Sports Medicine, University of Pretoria.

**Results.** Fifty-four per cent of the asymptomatic shoulders had tears. We found that the symptomatic tears were larger, appeared more chronic and had an associated biceps tendinopathy and glenohumeral joint effusion.

**Conclusion.** As other authors have found, the high incidence of asymptomatic tears indicates that rotator cuff tears can be regarded as a natural correlate of aging and that bilateral tears are common. Initial treatment should be conservative, but larger tears may benefit from early surgery before becoming chronic and causing glenohumeral dysfunction.

## Introduction

The aetiology of tendon failure in rotator cuff disease is generally considered to be multi-factorial. This includes extrinsic factors such as repetitive low-velocity micro-trauma and compression of the cuff by an abnormal coraco-acromial arch, and intrinsic factors such as poor cuff vascularity, alterations in collagen and age-related changes. Furthermore, it is generally believed that most full-thickness rotator cuff tears occur in the setting of already degenerated tendons, even when associated with trauma.<sup>4-6,8,9,12,14-16</sup>

The prevalence of tears is reported to be 30% in people older than 60 years, 50% in people at 70 years and more than 80% in people at 80 years.<sup>16</sup> Van Holsbeeck *et al.*<sup>16</sup> reported these ultrasound findings in 90 volunteer subjects who had never sought medical attention for shoulder disease. They showed no statistically significant differences in the prevalence of rotator cuff lesions in each gender for the dominant or non-dominant arm. They also found no statistically significant differences in the incidence of rotator cuff lesions related to gender or reported level of exertional activities. However, the prevalence of rotator cuff tears in both dominant and non-dominant arms showed a linear increase after the fifth decade of life. These results indicate that rotator cuff lesions may be regarded as a natural correlate of aging, with a statistically significant linear increase after the fifth decade of life.<sup>1,3,6,7,10,13,14,16,17</sup> With the use of fluoroscopy, Burkhart<sup>3</sup> concluded that the location rather than the size of the tear might be a more important factor in the resultant glenohumeral mechanics.

## CORRESPONDENCE:

Z Oschman  
PO Box 2090  
Groenkloof  
Pretoria  
0027  
Tel: 012-343 5000  
Fax: 012-343 0277  
E-mail: zanet@mweb.co.za

Findings on ultrasound that may distinguish asymptomatic from symptomatic tears have not been established. The aim of this study was to document the incidence of asymptomatic tears in patients with a confirmed symptomatic tear on the contralateral side and to look for any findings on ultrasound that may distinguish symptomatic from asymptomatic tears.

## Material and methods

The shoulders of 50 patients, 32 males and 18 females, with an average age of 64 years (range 40 - 83 years) were studied. The patients had a confirmed symptomatic rotator cuff tear on the one side and an asymptomatic shoulder on the contralateral side. The asymptomatic shoulder had no history of problems severe enough to have required medical attention. The patients completed a questionnaire regarding gender, age, race, history of shoulder pain, stiffness, weakness or any limitations on athletic activities or activities of daily living. All patients gave informed consent.

The accuracy of ultrasound in the assessment of full-thickness rotator cuff tears is well established in the literature. Studies carried out since 1986 show a consistent pattern with both high sensitivity and specificity particularly over the past 5 years, a trend reflecting improvements in ultrasound technology.<sup>11</sup> It is also a well-known fact that an ultrasound examination is operator-dependent. All the examinations in this study were done by the same experienced operator (ZO), a sports physician employed in a dedicated musculoskeletal ultrasound unit, with 15 years of ultrasound experience, including more than 10 000 shoulder examinations. The patients were examined using a Siemens Sonoline Elegra 7.5 MHz linear multi-frequency probe manufactured in Germany.

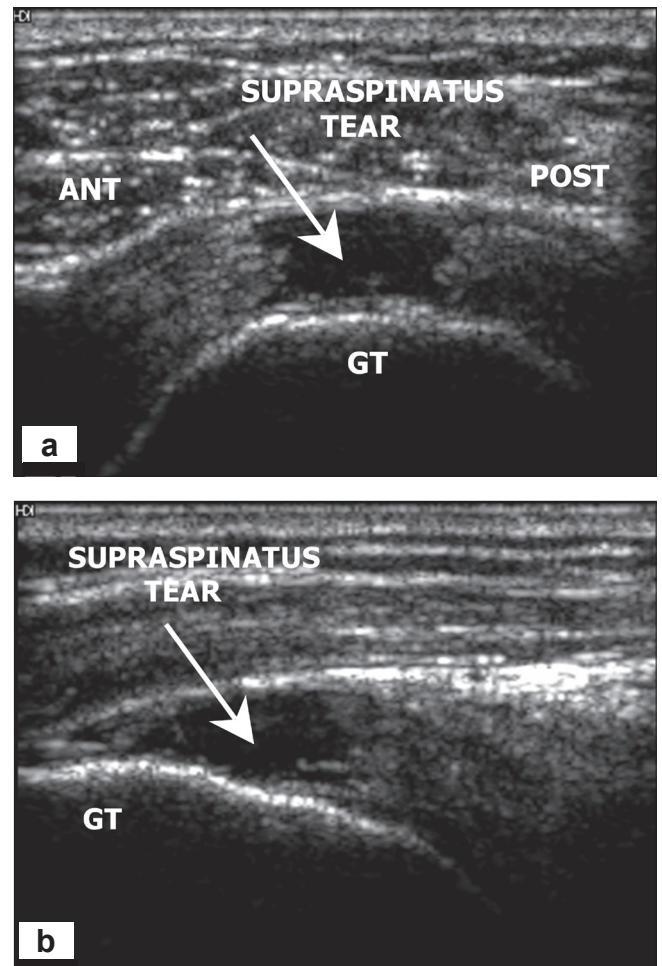
Both the symptomatic and asymptomatic tears were confirmed on ultrasound. The rotator cuff was examined with the arm in the neutral and adduction-internal rotation in the longitudinal (LONG) and transverse (TRV) planes. The appearance of the rotator cuff, subacromial-subdeltoid (SASD) bursa and long head of the biceps were documented. The antero-posterior (AP) dimension of the fat between the supraspinatus and trapezius muscles and the supraspinatus muscle was measured at the level of the suprascapular neurovascular bundle medial to the acromion. The maximum width and length of the tear was recorded with the arm in the adduction-internal rotation.

The majority of tears in this study were full-thickness tears involving the supraspinatus muscle. An entity called 'tear progression or creeping tears' involves smaller tears. There is little published on the natural history of small rotator cuff tears, and the answer to whether small tears progress to massive tears and the rate at which they might do so has yet to be fully established. Many patients with symptomatic rotator cuff tears are shown to have an asymptomatic tear on the contralateral side. Only some of these will become symptomatic and fewer will progress in size. In a 5-year follow-up study Yamaguchi and colleagues<sup>19</sup> showed that half of 45 asymptomatic tears studied became symptomatic on follow

up, but less than half of the 23 patients re-examined using ultrasound showed tear progression.

Full-thickness rotator cuff tears were diagnosed using the following criteria.<sup>18</sup>

Major criteria: any one of the following: (i) focal hypoechoic defect (Fig. 1); (ii) changes in cuff contour; (iii) absent cuff/naked tuberosity sign (Fig. 2); and (iv) communication between SASD bursa and glenohumeral joint.

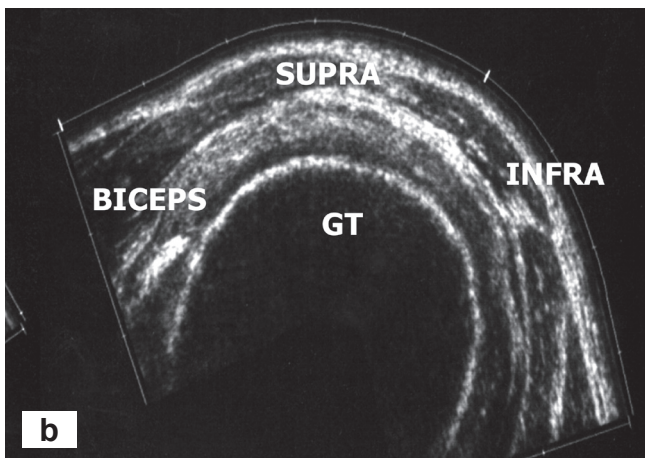
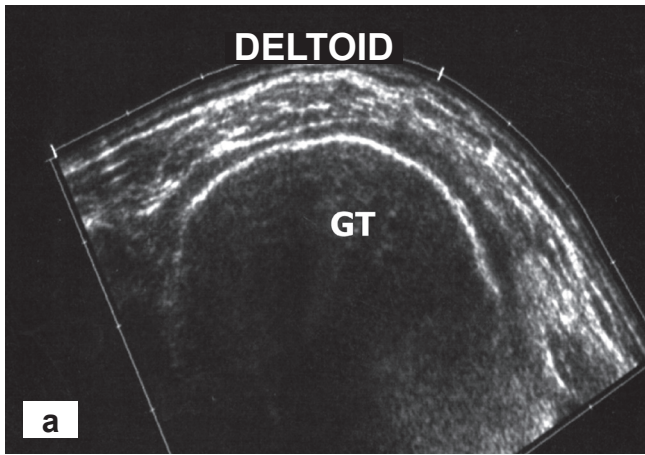


**Fig. 1. Full-thickness tear shown by the hypoechoic defect.**

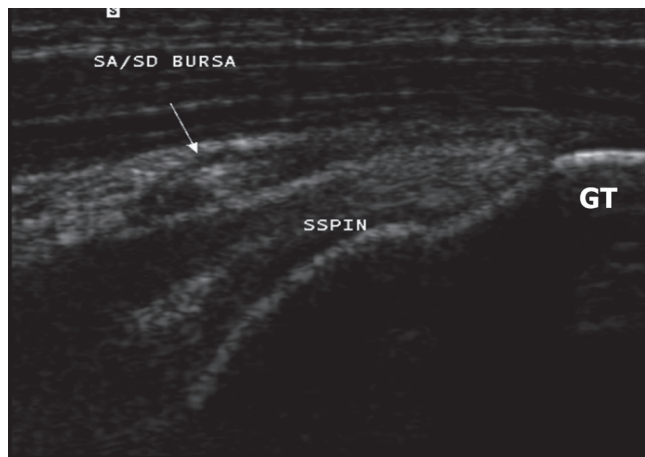
Minor criteria: any one of the following: (i) thickened SASD bursa (Fig. 3); (ii) SASD bursa fluid is a red flag for rotator cuff tear (Fig. 4); and (iii) bone changes.

Normally the fat between the supraspinatus and trapezius muscles is thin or barely seen. The normal supraspinatus muscle has a hypoechoic appearance caused by hypoechoic muscle bundles, separated by thin hyperechoic lines, the fibroadipose septae or perimysium.<sup>17</sup>

When there is a complete tear of the supraspinatus, there is retraction and atrophy of the muscle, with a decrease in AP dimension. The muscle becomes hyperechoic caused by a decrease in hypoechoic muscle bundles and an increase in hyperechoic fibroadipose septae and fat.<sup>11</sup> As the tear be-

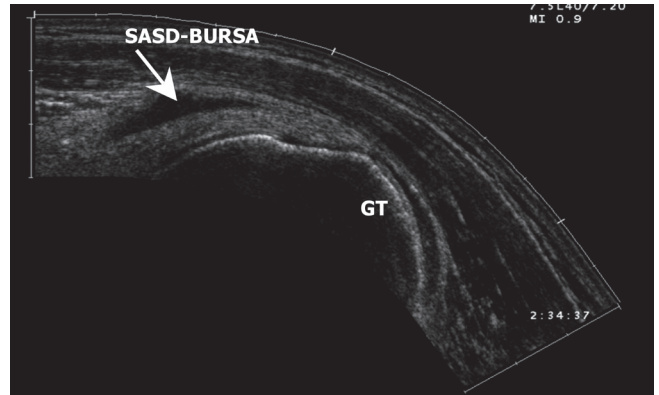


**Fig. 2. Transverse images of absent rotator cuff or naked tuberosity sign (a) and normal rotator cuff (b).**

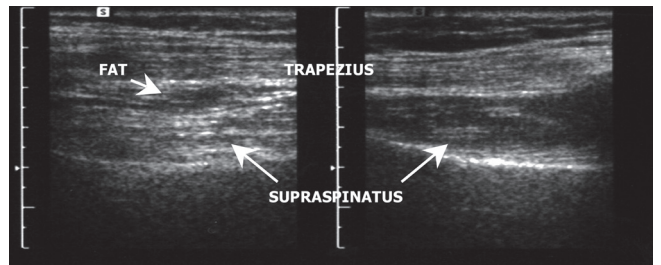


**Fig. 3. Longitudinal image of thickened SASD bursa.**

comes chronic the supraspinatus muscle atrophies and the AP dimension decreases, the space left is filled with fat, with an increase in the AP dimension of the fat between the supraspinatus and trapezius muscles (Fig. 5). These changes are readily appreciated on magnetic resonance imaging (MRI) with a loss of muscle bulk and increased signal on T1-weighted imaging reflecting atrophy. A number of studies have been directed at the assessment of supraspinatus muscle atrophy using ultrasound, but firm guidelines have



**Fig. 4. Longitudinal image of fluid in SASD bursa.**



**Fig. 5. Transverse images of the trapezius and supraspinatus muscles medial to the acromion. In (a) there is a chronic full-thickness tear of the supraspinatus with atrophy and fatty infiltration of the muscle and increased dimension of the fat between the trapezius and supraspinatus, (b) normal supraspinatus muscle.**

yet to be established.<sup>11</sup>

In this study we considered a tear acute when the supraspinatus muscle had a normal hypoechoic appearance and the fat between the supraspinatus muscle was thin or barely seen. We considered a tear chronic when there was atrophy of the muscle of the supraspinatus and an increase of the fat between the supraspinatus muscle and trapezius.

Confirmation of rotator cuff impingement is an important part of the routine ultrasound examination of the painful shoulder. Impingement refers to shoulder pain during abduction or abduction-flexion-internal rotation of the shoulder. The syndrome results from impingement of the soft tissues between the humerus, AC joint, acromion, and coraco-acromial ligament, and in the advanced stages causes rotator cuff tears and rotator cuff arthropathy.

Stages of impingement on ultrasound according to Neer are as follows:<sup>17</sup>

- Stage I - oedema and haemorrhage in the bursa and rotator cuff.
- Stage II - fibrosis and thickening of the bursa and partial rupture of the rotator cuff.
- Stage III - complete rupture of the rotator cuff.

The principal role of ultrasound is to determine what stage of impingement the disease has progressed to; this added information can be very helpful for treatment planning.<sup>11</sup> A



dynamic examination during active shoulder motion is also routinely performed to document if there is impingement.<sup>2</sup>

All the results were recorded on previously prepared computerised forms and photos were taken for documentation. A paired comparison using the Wilcoxon's non-parametric test was used, because distributions of differences were not normal. The chi-squared test was used to determine significant differences between the asymptomatic and symptomatic shoulders with regard to the number of ultrasound findings.

## Results

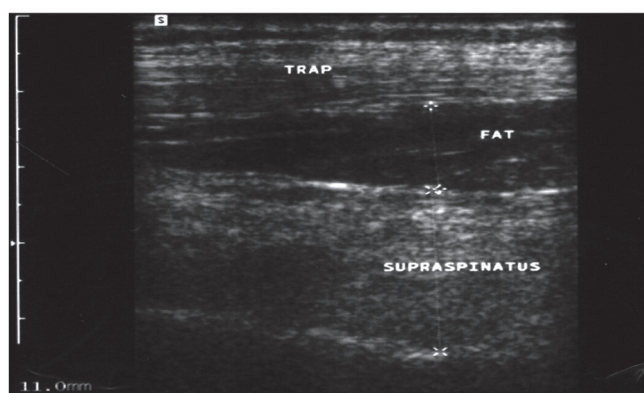
Twenty-seven patients (54%) had tears in their asymptomatic shoulders (i.e. these patients had bilateral tears). These results are higher than universally expected. Table I documents the tears according to age.

The mean standard deviation, and minimum and maximum width and length of the tears are given in Table II. According to the Wilcoxon's rank sum test the symptomatic tears were significantly larger in width ( $p = 0.0113$ ) and length ( $p = 0.0487$ ).

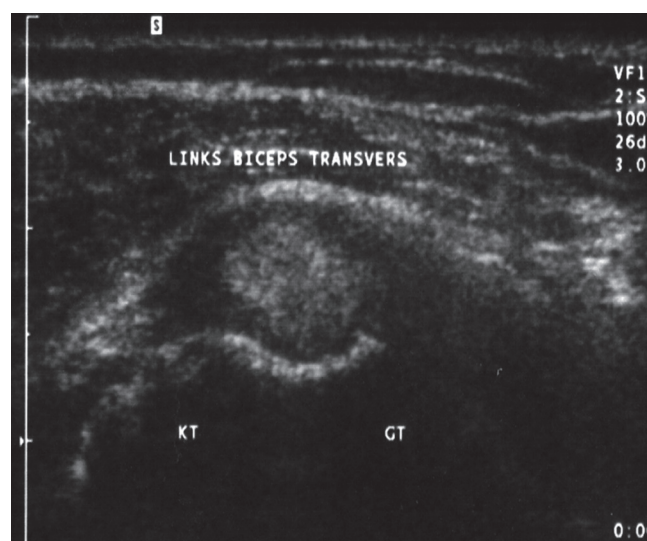
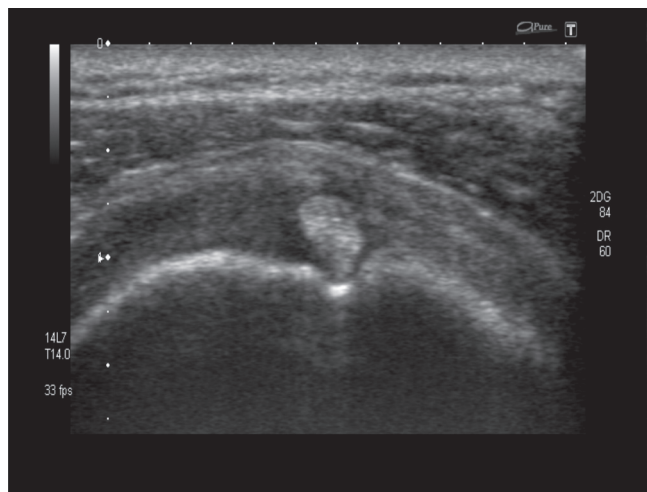
The AP dimension of the supraspinatus muscle and the AP dimension of the fat between the supraspinatus and trapezius muscles were measured (Fig. 6).

The Wilcoxon's rank sum test for paired data indicated that the symptomatic tears appeared more chronic, with significant atrophy of the muscle of the supraspinatus ( $p = 0.0001$ ) and significant increased thickness of the fat between the muscles of the supraspinatus and trapezius ( $p = 0.0002$ ). Table III gives the mean, standard deviation minimum and maximum in millimetres for the symptomatic and asymptomatic shoulders.

The presence of other findings on ultrasound were recorded in the symptomatic and asymptomatic shoulders, the appearance of the biceps tendon, SASD bursa, the presence of a glenohumeral joint effusion, signs of impingement according to Neer's classification and size of the tears.<sup>17</sup> When there is a full-thickness rotator cuff tear present, the space between



**Fig. 6. Chronic supraspinatus tear with atrophy and fatty infiltration of the muscle and increased dimension of the fat between the supraspinatus and trapezius muscles.**



**Fig. 7. Transverse image of normal biceps (a) and biceps tendonopathy (b).**

the glenohumeral joint and the SASD bursa is continuous, thus it is impossible to distinguish between SASD bursa effusion and a glenohumeral joint effusion. In patients with full thickness tears, we reported the fluid as glenohumeral when it was located mainly in the biceps sheath and the posterior glenohumeral joint recess, but not in the bursa.

If the biceps tendon appeared thickened/ thinned with a hypoechoic heterogenic image, it was documented as a biceps tendonopathy (Fig. 7).

The normal SASD bursa is not thicker than the humeral head cartilage and does not contain fluid. If the bursa contained fluid (Fig. 4) and appeared thickened (Fig. 3) it was

**TABLE I. Percentage with tears in asymptomatic shoulder for each age group**

Age group (years)	Percentage
40 - 59 (20 patients)	35
60 - 69 (13 patients)	54
70 - 83 (17 patients)	77

**TABLE II. Size of tears in symptomatic and asymptomatic shoulders**

Size of tears (mm)	Symptomatic shoulder (N = 27)	Asymptomatic shoulder (N = 27)	Wilcoxon's p-value
Mean width	16.70	3.44	0.0113
Standard deviation of width	9.59	11.30	
Minimum width	2.00	2.00	
Maximum width	40.00	40.00	
Mean length	18.19	15.33	0.0487
Standard deviation of length	10.70	10.24	
Minimum length	2.00	3.00	
Maximum length	36.00	32.00	

**TABLE III. AP dimensions of the supraspinatus muscle (N = 49) and fat (N = 50) between the supraspinatus and trapezius muscles**

AP dimensions (mm)	Symptomatic shoulder	Asymptomatic shoulder	Wilcoxon's p-value
Mean supraspinatus	18.90	20.47	0.0001
Standard deviation of supraspinatus	4.36	4.58	
Minimum supraspinatus	6.00	8.00	
Maximum supraspinatus	27.00	29.00	
Mean fat	6.92	5.32	0.0002
Standard deviation of fat	2.57	2.49	
Minimum fat	0	0	
Maximum fat	14.00	11.00	

**TABLE IV. Number of other imaging findings (N = 50)**

Imaging findings	Both shoulders	Only symptomatic shoulder	Only asymptomatic shoulder	Not present
Biceps tendinopathy	13	24	2	11
SASD bursitis	38	11	1	0
Glenohumeral joint effusion	11	24	0	15
Impingement	43	7	0	0
Tear present	27	23	0	0

**TABLE V. Estimated probability of other findings present only in symptomatic shoulder**

Imaging findings	Probability
Glenohumeral joint effusion	0.686
Biceps tendinopathy	0.649
Grade of tear	0.460
SASD bursitis	0.224
Signs of impingement	0.140

**TABLE VI. Number of other findings per shoulder**

Findings	0	1	2	3	4	5
Symptomatic	0	0	0	7	15	28
Asymptomatic	5	1	17	15	5	7

documented as a SASD bursitis.<sup>18</sup> The incidence of these findings in the asymptomatic and symptomatic shoulders is recorded in Table IV.

The estimated probability of the presence of these findings in the symptomatic shoulder is given in Table V. The highest probability is associated with glenohumeral joint effusion (0.686). Relative to the other findings, a glenohumeral joint effusion is the strongest indicator of pain. The second strongest indicator of pain is biceps tendinopathy (0.649). The weakest indicator is signs of impingement (0.140).

It is also necessary to consider the incidence of these findings being an indicator of pain. The question might be raised whether there are a different number of findings present in the symptomatic and asymptomatic shoulders. Table VI gives the number of shoulders on the symptomatic and asymptomatic sides with 0, 1 and up to 5 other findings present.

A chi-squared test of independence indicated that there is a significant difference ( $P = 0.0001$ ) between the asymptomatic and symptomatic shoulders with regard to the number of other ultrasound findings present. It can be seen that a high percentage of symptomatic shoulders have more than 3 other findings, while a relatively high percentage of asymptomatic shoulders have 3 or less findings.

## Discussion

The aim of the study was to examine the integrity of the asymptomatic rotator cuff in patients with a confirmed symptomatic rotator cuff tear on ultrasound in the opposite shoulder, and to identify any other relevant ultrasound findings that would distinguish symptomatic from asymptomatic tears.

The high incidence of asymptomatic tears in the study group indicate, as other authors have found, that rotator cuff tears can be regarded as a natural correlate of aging and that bilateral tears are common.<sup>11,12</sup> From Table IV one can deduce that with all 5 other findings present it is highly likely that the shoulder will be painful. Good indicators of pain were the presence of a glenohumeral joint effusion and biceps tendinopathy, which could be indicators of glenohumeral dysfunction.

Although the asymptomatic shoulders have a high prevalence of tears, we also found that the tears in the symptomatic shoulders were significantly larger and more chronic. The presence of a tear does not indicate a source of pain; it seems that pain might be caused by the size of the tear and not necessarily the mere existence of a tear. But one must realise, as shown in Table VI, that the asymptomatic shoulder may have similar or more ultrasound findings.

Therefore the decision to operate based on size of tear is not yet clear. Our study indicates that larger tears may benefit from early surgery before becoming chronic and causing glenohumeral dysfunction.

## REFERENCES

1. Bouffard JA, Lee S, Dhanju J. Ultrasonography of the shoulder. *Semin Ultrasound CT MRI* 2000; 21:164-91.
2. Breckon C, Davidson D. Understanding the shoulder complex and comprehensive management of common conditions. Johannesburg, Centre for Sports Medicine and Orthopaedics, 2006.
3. Burkhart SS. Fluoroscopic comparison of kinematic patterns in massive rotator cuff tears. A suspension bridge model. *Clin Orthop* 1992; 284:144-52.
4. Calvert PT, Packer NP, Stoker DJ, Bayley JI, Kessel L. Arthrography of the shoulder after operative repair of the torn rotator cuff. *J Bone Joint Surg Br* 1986; 68(1): 147-50.
5. Cardinal E. Dynamic ultrasound of musculoskeletal pathology. 16th Annual Conference of the Musculoskeletal Ultrasound Society, Seoul, Korea, 27 May - 1 June 2006.
6. De Palma AF. *Surgery of the Shoulder*. 3rd ed. Philadelphia: JB Lippincott, 1983.
7. Hawkins R. Rotator cuff tears. Presented at the Orthopaedic Symposium on Rotator Cuff Tears. Antwerp, Belgium, 24-25 February 1989: 25.
8. Iannotti JP. *The Rotator Cuff: Current Concepts and Complex Problems*. Rosemont Ill.: American Academy of Orthopaedic Surgeons, 1998: 1-12.
9. Jacobson JA. Ultrasound in sports medicine. *Radiol Clin North Am* 2002; 40:364-70.
10. Marcellis S, Jager T. *Musculoskeletal Ultrasound*. Aloka Clinical Library Series I, 2006.
11. McNally EG. *Practical Musculoskeletal Ultrasound*. Amsterdam: Elsevier, 2005: 44,48,50,54.
12. Milgram C, Schaffler M, Gilbert S, Van Holsbeeck MT. Rotator cuff changes in asymptomatic adults. *J Bone Joint Surg Br* 1995; 77:296-8.
13. Rockwood CA, Burkhead WZ. Management of patients with massive rotator cuff defects by acromioplasty and rotator cuff debridement. *Orthop Trans* 1988; 12:190-1.
14. Sher JS, Uribe JW, Posada A, et al. Abnormal findings on magnetic resonance images of asymptomatic shoulders. *J Bone Joint Surg Am* 1995; 77:10-4.
15. Teefey SA, William MD, Middleton MD. Shoulder sonography, state of the art. *Radiol Clin North Am* 1999; 37:772-3.
16. Van Holsbeeck MT, Graig JG, Booffard JA. Radiological Society of North America Special Course in Ultrasound, 1996: 117-23.
17. Van Holsbeeck MT, Introcaso JH. *Musculoskeletal Ultrasound*. 2nd ed. Philadelphia: Mosby, 2001: 27,465, 477-87.
18. Van Holsbeeck MT, Kolowich PA. Anatomy, physical examination and ultrasound of the shoulder. 16th Annual Conference of the Musculoskeletal Ultrasound Society, Seoul, Korea, 27 May - 1 June 2006.
19. Yamaguchi K, Tetro AM, Blam O, Evanoff BA, Teefey SA, Middleton WD. Natural history of asymptomatic rotator cuff tears: a longitudinal analysis of asymptomatic tears detected sonographically. *J Shoulder Elbow Surg* 2001; 10:199-203.